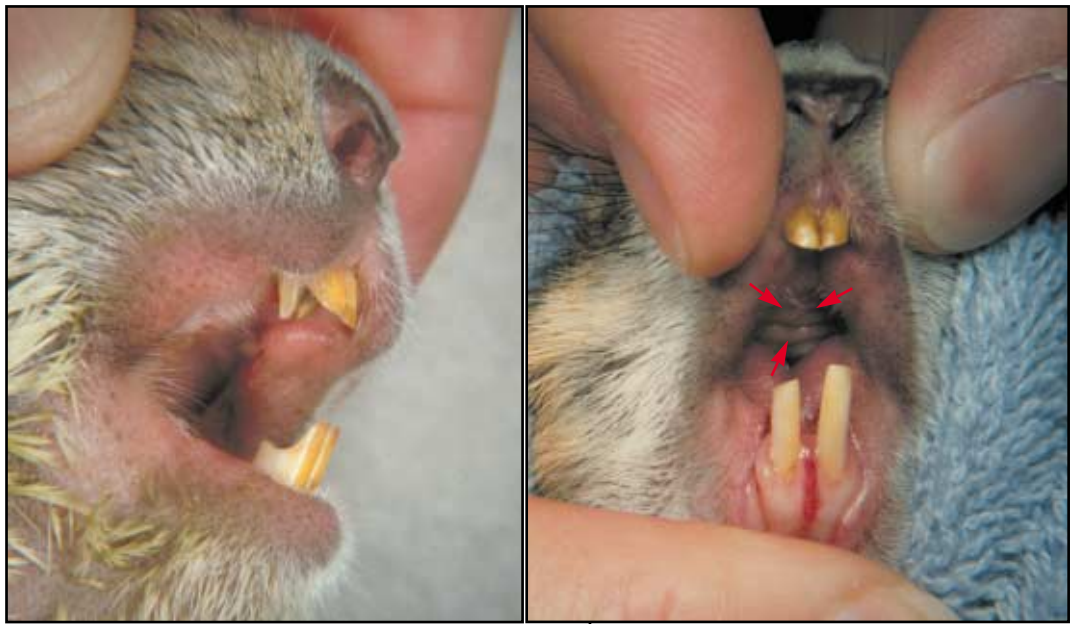

Diagnosing Odontomas in Prairie Dogs*

Complex odontoma should be included in the differential for prairie dogs with respiratory signs. Prevention or elimination of chronic upper incisor trauma is an important first step in the management of this condition.



ROBERT A. WAGNER, VMD
Lab Animal Resources
University of Pittsburgh
Pittsburgh, Pennsylvania

ROBERT H. GARMAN, DVM,
DACVP
Consultants in Veterinary
Pathology
Murrysville, Pennsylvania

BOBBY M. COLLINS, DDS
School of Dental Medicine
University of Pittsburgh

Robert Wagner received his VMD degree from the University of Pennsylvania in 1981. He currently serves as Clinical Assistant Professor of Veterinary Medicine, University of Pittsburgh, and as a part-time exotic animal clinician at the Fox Chapel Animal Hospital in Pittsburgh.

*Adapted in part from Proceedings American Association of Zoo Veterinarians, 1997, p 219

Ten Black-tailed Prairie Dogs (*Cynomys ludovicianus*) were presented with upper respiratory symptoms of varying degree. The animals (5 male, 5 female) were privately owned, originating from different breeders, and were 2.5-6 years of age.

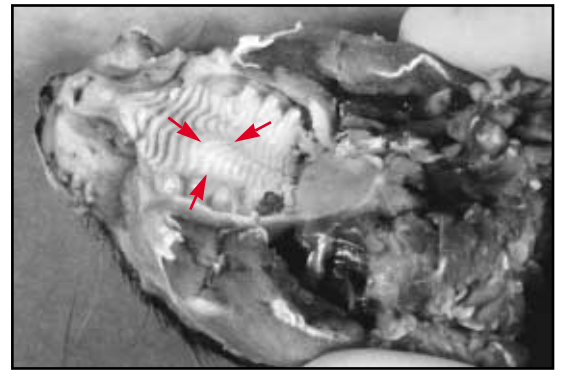
Clinical Signs

The primary clinical signs were dyspnea, stridor, partial or complete obstruction of nasal air flow, open-mouthed breathing and occasional nasal discharge. Values for hematology and serum chemistry profiles were within normal reference ranges for the animals tested.

All animals had malocclusion of the incisors or a history of dental trauma, such as chewing hard materials: metal or plastic cages, rocks or toys.

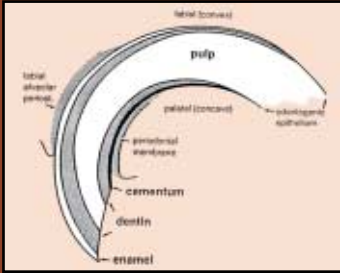
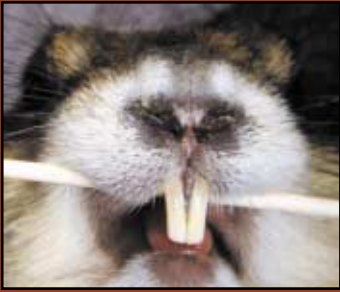Physical exam revealed nodular hard palate lesions in seven of the ten animals (arrows). The hard palate lesions were unilateral or bilateral and were characterized histologically as complex odontomas. The size of the hard palate lesions did not appear to correlate with the degree of respiratory distress.

Pathologic attrition or notching of upper incisors due to malocclusion is a common finding in prairie dogs with complex odontomas. Physical examination of this prairie dog indicates the upper incisors are shortened from chewing hard materials and other dental trauma.



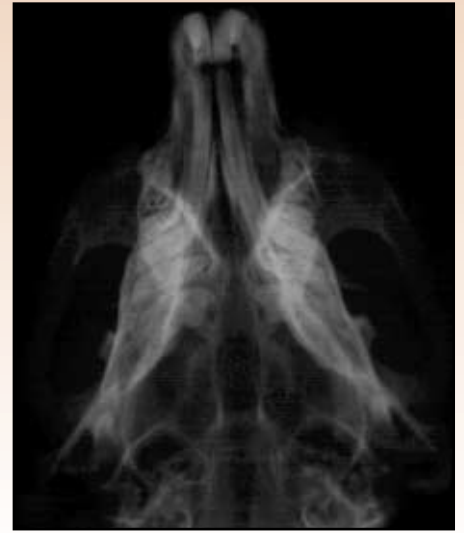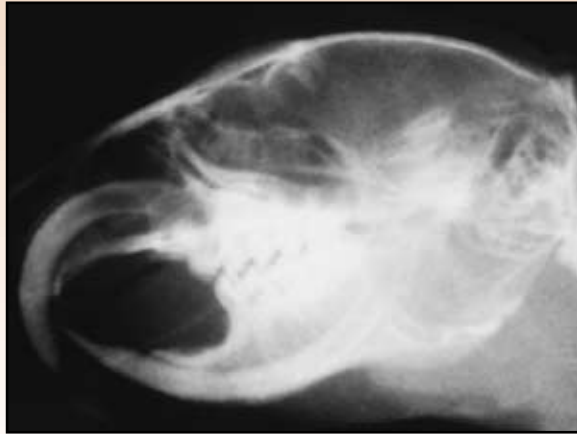Clinical presentation was highly suggestive of the disease; visualization of the tumor on the hard palate or on skull radiographs was diagnostic in all cases.

ROBERT A. WAGNER, VMD



Normal Incisor!

Normal Prairie Dog



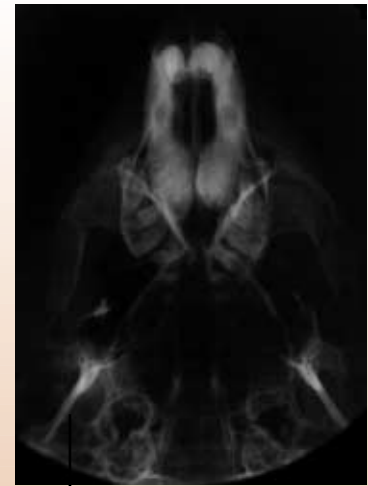
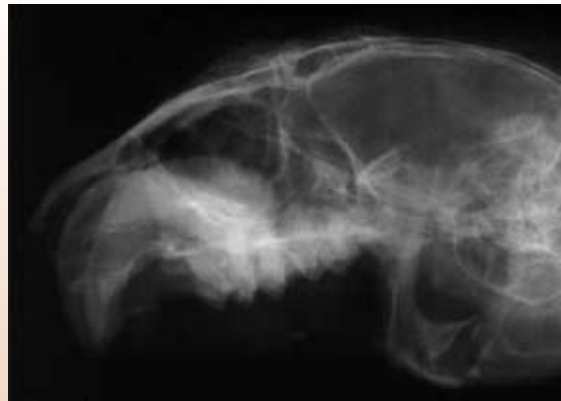1 Lateral and ventrodorsal radiographs of a normal Black-tailed Prairie Dog skull show uniform width of teeth in apical segment that are symmetrical and elongated.

Contrast Studies

All animals in this study had radiographic lesions consistent with hypercementosis, complex odontomas and obstruction of nasal air passage. Although the clinician is able to appreciate the lesion(s) without contrast radiography, to illustrate the area most commonly obstructed by the tumor, 1-2 ml of contrast medium was injected into the nostril of an anesthetized animal immediately prior to radiography.

Both barium and Renografin® have been used on live prairie dogs for skull contrast studies. Good contrast is difficult because air movement through the nostrils quickly removes the medium. Renografin® is less likely to be aspirated, but barium adheres better to the nasal mucosa for improved contrast.

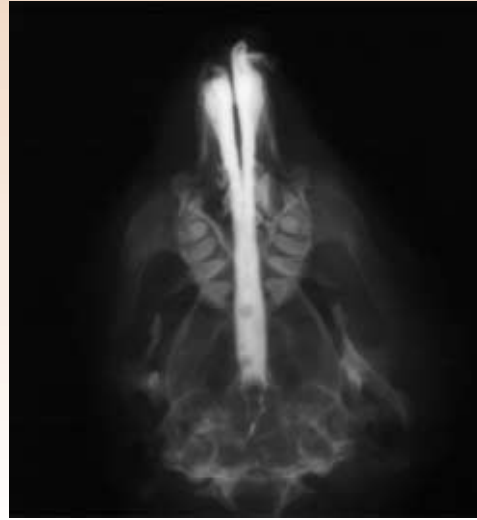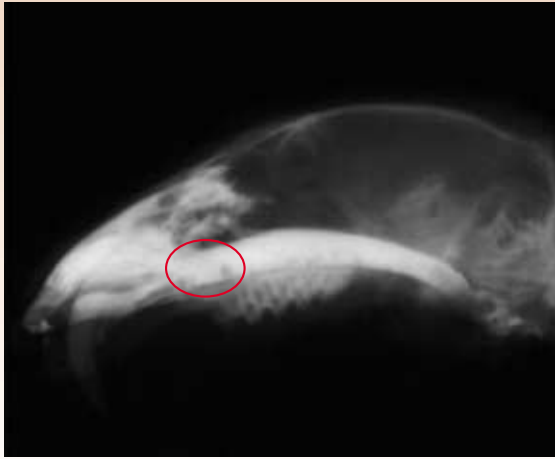
Affected Prairie Dog



2 Bilateral tumor causes bulbous radiopacity in apical half of central incisor teeth.

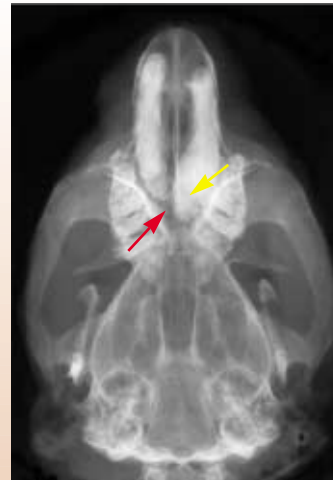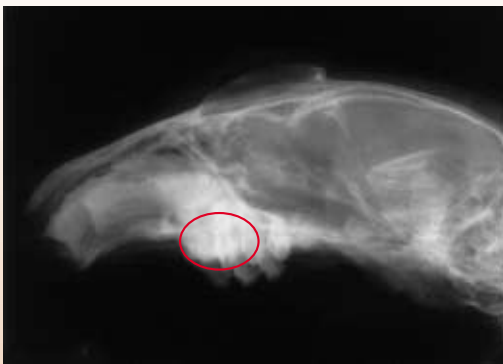3 Asymmetric apical enlargement of incisor teeth. Roots are encroaching on midline.

Contrast Study of Normal Prairie Dog



4 Lateral and ventrodorsal barium contrast study of normal nasal respiratory anatomy in Black-tailed Prairie Dogs. Note the sharp angle narrow air passage of the nasal cavity in its relation to the apex of the incisors (*circled*).

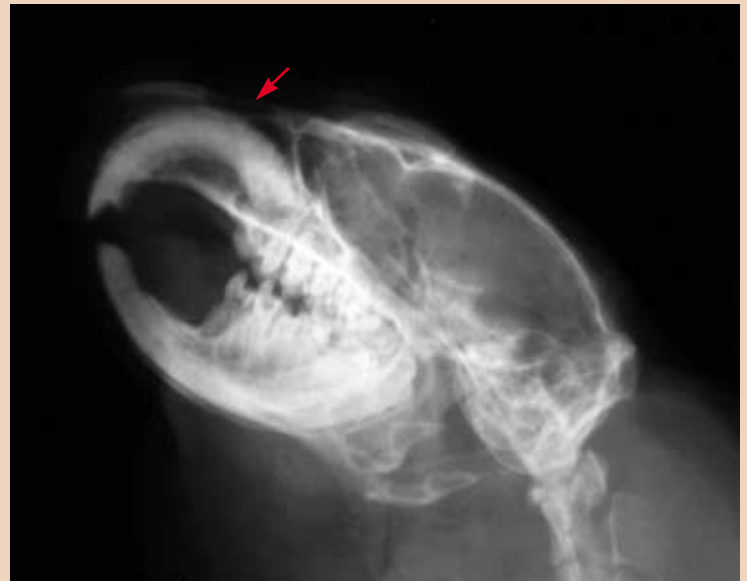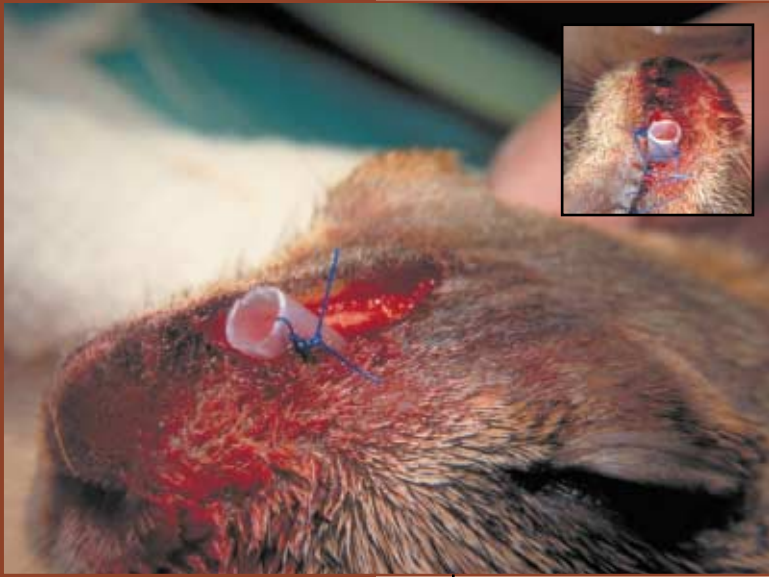
Affected Prairie Dog



5 Lateral radiograph of enlarged apical half of incisor, superior aspect of cemental surface is irregular and serrated. Note large odontoma distorting hard palate (*circled*).

6 Radiograph (inferior view) of asymmetric apical enlargement. The right apices is larger and has a cleft (*yellow arrow*) with additional radiopaque material medial and distal to bulk of tooth, considered to be a complex odontoma (*red arrow*). Both roots are bulbous.

[Surgery for severely dyspneic animals appears to be the only successful treatment at this time]



Therapy Attempts

Medical treatment with antibiotics, decongestants and steroids was palliative in the prairie dogs studied. Attempted extraction of the incisors often resulted in fractured incisors and incomplete removal and did not alleviate clinical signs. Tracheostomy eliminated the signs of upper airway obstruction, but patency was difficult to maintain.

References

1. Kuijpers MHM, Aart JvdK, Slootweg PJ: The rat incisor in toxicologic pathology. *Toxicologic Pathol* 24(3):346, 1996.
2. Losco PE: Dental dysplasia in rats and mice. *Toxicologic Pathol* 23(6):667, 1995.

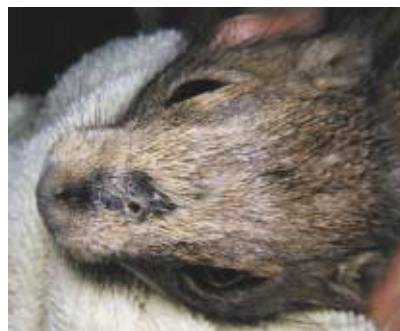9 Placement of a hard plastic catheter through a unilateral rhinotomy site past the tumor eliminated the respiratory distress in two of the animals in which surgery was performed.

10 Radiograph of rhinotomy site, right side, with plastic catheter in place.

RISK FACTOR

1 2 3 4 5

SUMMARY



Odontoma appears to be a common cause of upper respiratory symptoms in captive Black-tailed Prairie Dogs. It is suspected that odontogenic tumors are hamartomous growths, developing in reaction to mechanical trauma of the upper incisors, but other causes

cannot be eliminated. Prevention or elimination of chronic upper incisor trauma is an important first step in the management of this condition. Surgery for severely dyspneic animals appears to be the only successful treatment at this time.